

The effects of dexamethasone and erythropoietin on mice sciatic nerve crush injury: histopathologic and functional outcomes

Nikta Mansouri¹, Hamidreza Fattahian^{1*}, Alireza Jahandideh¹, Hesameddin Akbarein²

Submitted: 10/04/2022

Accepted: 07/07/2023

¹Department of clinical sciences, Science and Research Branch, Islamic Azad University, Tehran, Iran

²Department of food hygiene and quality control, University of Tehran, Tehran, Iran

*Corresponding author: hamidrezafattahian@yahoo.com

Abstract: Peripheral neuropathies are one of the major causes of motor and sensory disability. The multitude of nerve injuries and associated comorbidities provides a strong impetus to find a drug that potentiate or accelerate axonal regeneration. Systemic drug delivery has been a promising strategy in this regard. This study aimed to evaluate dexamethasone and erythropoietin effects on sciatic nerve regeneration. Twenty-three mice were randomly assigned to sham, control, dexamethasone, erythropoietin, and dexamethasone + erythropoietin groups. The left sciatic nerve was crushed using mosquito hemostatic forceps. Medications were administered once daily for 28 days. The sham group received neither crush injury nor medication. Histopathologic and walking track analyses were performed. Medical therapy influence on functional recovery was observed in as soon as 14 days. Although functional recovery was superior in the dexamethasone + erythropoietin group, a complete return to near-normal function was seen after 28 days in all of the groups. Dexamethasone yielded superior SFI values compared to the erythropoietin on day 14, although this was not statistically significant ($p = 0.534$). Histopathologically, recovery of average axonal number up to 75% normal nerve and significant decline of axonal swelling was observed in the erythropoietin and dexamethasone + erythropoietin groups, which were statistically significant compared to the dexamethasone group ($p = 0.008$). Marked immunoreactivity to Glial fibrillary acidic protein (GFAP) was present in the dexamethasone group. Furthermore, immunoreactivity to S-100 protein was observed in regenerated nerves in all groups. Present data provide insights into the neurotrophic effects of dexamethasone and erythropoietin on sciatic crush; however, further investigation is required to justify the clinical application of these agents.

Keywords: Sciatic nerve, dexamethasone, erythropoietin, histopathology, regeneration

1. Introduction

Peripheral nerve injury (PNI) can be the consequence of multiple clinical scenarios such as road accidents, falls, gunshot wounds, stretching or crushing traumas, and iatrogenic injuries (Araújo-Filho et al., 2016; Chen et al., 2017). Recovery following PNI is often incomplete and unsatisfactory. Sensory and motor deficits lead to intractable neuropathic pain or everlasting disability that affects patient quality of life. Therefore, PNI is an essential health-threatening concern of the present era (Grinsell and Keating, 2014; Imran et al., 2019; Jones, Eisenberg, and Jia, 2016; Lin et al. 2018). Despite decades of trial and error, the prognosis of peripheral neuropathy remained unpredictable. The core challenge of research is to accelerate axonal outgrowth and re-myelination before irreversible atrophy of distal muscles due to chronic denervation (Chen et al., 2017; Panagopoulos, Megaloikonomos, and Mavrogenis, 2017; Mekaj et al., 2014, Sun et al., 2012).

Following peripheral nerve compression, an inflammatory response ensues. Glucocorticoids such as dexamethasone decrease inflammation and its undesirable consequences. Among synthetic glucocorticoids, dexamethasone received the primary focus in several studies because of its availability, high potency, prolonged half-life, and cost-effectiveness (Uzun et al., 2019; de Souza et al., 2018; Feng and Yuan, 2015; Jang et al., 2014). The well-recognized mechanisms by which corticosteroids diminish inflammation and promote recovery include reduction of inflammatory mediators, local edema, lipid peroxidation, as well as decreasing scar formation and neuropathic pain (Mohammadi, Azad-Tirgan, and, Amini, 2013; Shishido et al., 2002; Wang et al., 2015; Seth et al., 2012).

The renal cytokine, erythropoietin (EPO) is also an FDA-approved drug that regulates hematopoiesis. Erythropoietin plays a beneficial role in poly-trauma patients suffering nerve injury and anemia simultaneously. Recently, evidence supporting the in vitro and in vivo neurotrophic and neuroprotective effects of erythropoietin has been gathered (Elfar et al., 2008; Geary et al., 2017, Wang et al., 2015). Reduction of lipid peroxidation and glutamate toxicity, inhibition of apoptosis and neuroinflammation and stimulation of axonal regrowth are some of the major reported erythropoietin neuro-beneficial roles (Yin et al., 2010; Sundem et al., 2016). Neurons and Schwann cells of the sciatic nerve both express erythropoietin receptors. These receptors upregulate following nerve injury to promote regeneration by regrowth and myelination of injured axons, restoration of synaptic connections, and recovery of physiological functions (Geary et al., 2017; Wang et al., 2015; Sundem et al., 2016). Erythropoietin minimal adverse effects and safety of therapeutic doses make it an excellent candidate for upcoming peripheral nerve experiments (Geary et al., 2017; Sundem et al., 2016).

Rodent sciatic nerve has been the preferred model in nerve regeneration experiments probably due to cost-effectiveness, ease of handling, high regenerative capacity, and rapid regeneration resembling humans (Uzun et al., 2019; de Souza et al., 2018). Histomorphometric, electrophysiological and functional evaluations have been the most popular methods employed in these studies (Suslu et al., 2013). The sciatic functional index (SFI), first introduced by Medinaceli et al. and modified by Bain et al. is the gold standard for sciatic nerve function evaluation, because not only it is a non-invasive, reliable, inexpensive index but also the results are measurable quantities with repeatability (de Souza et al., 2018; Yin et al., 2010; Suslu et al., 2013). SFI evaluates proper walking which requires coordinated function involving sensory and motor response and cortical integration (Feng and Yuan, 2015; Suslu et al., 2013).

Peripheral nerves have strong regenerative capacity especially after mild injuries such as nerve crush. Diverse approaches such as early surgical repair, rehabilitation techniques, tissue engineering and application of various growth factors, hormones, biomaterials and medications have been under researchers focus to find ideal solutions for peripheral nerve injuries. Each of the aforementioned solutions have advantages and disadvantages, some have short-term or long-term complications and few didn't show promising results (Jones, Eisenberg, and Jia, 2016; Panagopoulos, Megaloikonomos, and Mavrogenis, 2017; Mekaj et al., 2014). Pharmacotherapy with neuroprotective, immunosuppressive and regenerative therapeutic agents and supplements have shown favorable outcomes in peripheral nerve regeneration (Imran et al., 2019; Lin et al. 2018; Panagopoulos, Megaloikonomos, and Mavrogenis, 2017).

Currently there is no clinically available and curative pharmacologic treatment. Combining two pharmaceutical agents to unveil their possible synergism is a recent strategy (Sun et al., 2012; Uzun et al., 2019; Yuce et al., 2015). Few studies have been published concerning simultaneous administration of corticosteroids and erythropoietin, and controversial results were reported regarding their synergistic or antagonistic effects (Bernstein et al., 2016; Diem et al., 2005; Lee et al., 2020; Zamani et al., 2018). The purpose of this study was to evaluate individual neurotrophic influences and also probable synergistic effects of erythropoietin and dexamethasone on sciatic nerve crush injury in mice.

2. Materials and Methods

2.1. Animals

A total of 23 adult male Swiss mice with an average body weight of 30 gr were used. Animals were housed in wood-chip-lined plastic cages under 12-hour light-dark cycle for one week for adaptation purposes. Standard rodent diet, and water ad libitum were provided.

2.2. Experimental design and surgical procedure

Mice were randomly assigned to groups of five for the experimental groups and three for the sham group. A color code was applied to the tail of each animal to allow for blinded identification. Animals were anesthetized by intramuscular injection of 0.2 mg/kg of medetomidine (Dorben Vet, Spain) and 30 mg/kg of 10% ketamine hydrochloride (Alfamin, Alfasan International BV, Woerden, The Netherlands). Surgery was done under aseptic condition using an operating microscope (Topcan, OMS-90, Tokyo, Japan). A one cm incision was made on left lateral thigh of each mouse. The sciatic nerve was exposed after caudal retraction of biceps femoris muscle and crushed with a 2mm width fine hemostatic forceps (Schreiber, Fridingen, Germany); 5 mm above the sciatic nerve trifurcation for 10 seconds. Manifestation of a translucent band across the nerve confirmed the crush completion and a marker was applied on the biceps femoris fascia with a 5-0 nylon suture material. The muscle and skin layers were sutured routinely. Sham-operation mice were submitted to sciatic nerve exposure without crushing. After the surgery, mice were treated once daily for 28 days as follows:

Sham-operation group (n = 3): received no medication.

Control group (n = 5): Saline 0.9% was administered as a standardization measure for the procedure.

Dexamethasone Group (n = 5): 2 mg/kg systemic (Sun et al., 2012; de Souza et al., 2018, Feng et al., 2015) dexamethasone 8 mg/2 ml in the form of ampules (Iran Hormone, Tehran, Iran).

Erythropoietin Group (n = 5): 5000 U/kg subcutaneous erythropoietin (Geary et al., 2017; Wang et al., 2015; Suslu et al., 2013). (Pooyesh Darou Biopharmaceutical Co., Tehran, Iran).

Dexamethasone + erythropoietin Group (n = 5): Both drugs were administered with mentioned dosages.

2.3. Walking track analysis

SFI was measured based on formula developed previously by Inserra, Bloch, and Terris (1998). Analysis was performed on day 0 before the surgery to obtain a baseline analysis and on postoperative days 1, 14 and 28. Mice were put on a walking track (49 × 15 × 8 cm) darkened at one end. White paper with appropriate dimensions was placed on the bottom of the track. Animals' hind limbs were dipped in blue ink, and they were permitted to walk through the track,

leaving their footprints on the paper. An index value of 0 sets as normal functioning whereas that of -100 represents total loss of functioning.

2.4. Histological evaluation

Four weeks after the surgery, animals were euthanized with pentobarbital (300 mg/kg). The nerve was re-exposed using the previously described operative approach and dissected from the surrounding tissues. A 5 mm segment of the sciatic nerve containing the exact crushed site and areas proximal and distal to it were harvested carefully. Samples were fixed in 10% formaldehyde and were paraffin wax-embedded. Five μ m thick longitudinal serial sections were obtained using a microtome, stained with hematoxylin-eosin, and assessed by light microscopy to disclose the histopathological elements of the tissue. Toluidine blue staining was also performed on cross-sections of the nerve to assess the quality of regenerated nerves, neural architectural characteristics, and describe elements of tissue inflammation.

2.5. Immunohistochemistry

The expression of the glial fibrillary acidic protein (GFAP) was evaluated as a hallmark of Schwann cells and astrocytes activation throughout nerve regeneration. In addition, anti-S-100 was used as a marker for the myelin sheath. Staining intensity was rated by light microscopy as negative (-), weakly positive (+), moderately positive (++), and marked positive (+++).

2.6. Gross observations

A gross macroscopic assessment was done on day 28. The sciatic nerve was exposed and presence of self-mutilation, local infection, and inflammation were inspected. Furthermore, muscle adhesion, tissue derangement, adherence of the nerve to the surrounding muscle cavity, muscle fascia closure as well as the skin closure were evaluated by qualitative scoring as previously described (Inserra, Bloch, and Terris (1998), with the modifications indicated below. Concerning muscle adhesion, negative (-) reflected no muscle adhesion whereas weak (+), moderate (++), and marked (+++) indicated minimal, moderate and severe adhesion respectively. Similarly, tissue derangement was compared between groups so that negative (-) reflected no tissue derangement, weak (+) reflected the lowest degree of derangement, and marked (+++) reflected the maximum degree. Regarding nerve adherence to the surrounding muscle cavity, negative (-) indicated that the nerve was either free or required minimal blunt dissection to separate. Furthermore, weak (+), moderate (++), and marked (+++) reflected that mild blunt dissection, moderate blunt dissection, and sharp dissection with scissors was required for separation, respectively. Regarding muscle fascia and skin closure, (+) reflected complete closure and (-) reflected failure of the wound to close.

2.7. Statistical analysis

Statistical analyses were done by SPSS software version 26.0. The descriptive statistics were described by mean \pm SEM. An analysis of one-way ANOVA was done each time. Furthermore, an analysis of LSD Post Hoc was performed between groups on day 28. The repeated measures with a 95% confidence interval were carried out by the general linear model procedure for times trends measures. $p < 0.05$ was considered statistically significant.

3. Results

3.1. Walking track analysis

According to the repeated measures with a 95% confidence interval, SFI values trends of all groups were significantly different in measured times except for the sham group ($p < 0.001$). SFI values on day 1 postoperative (before medication administration) were significantly different relative to the baseline values (day zero, before the operation) in all groups ($p < 0.001$) excluding the sham group ($p = 0.6$), (Figure 1a).

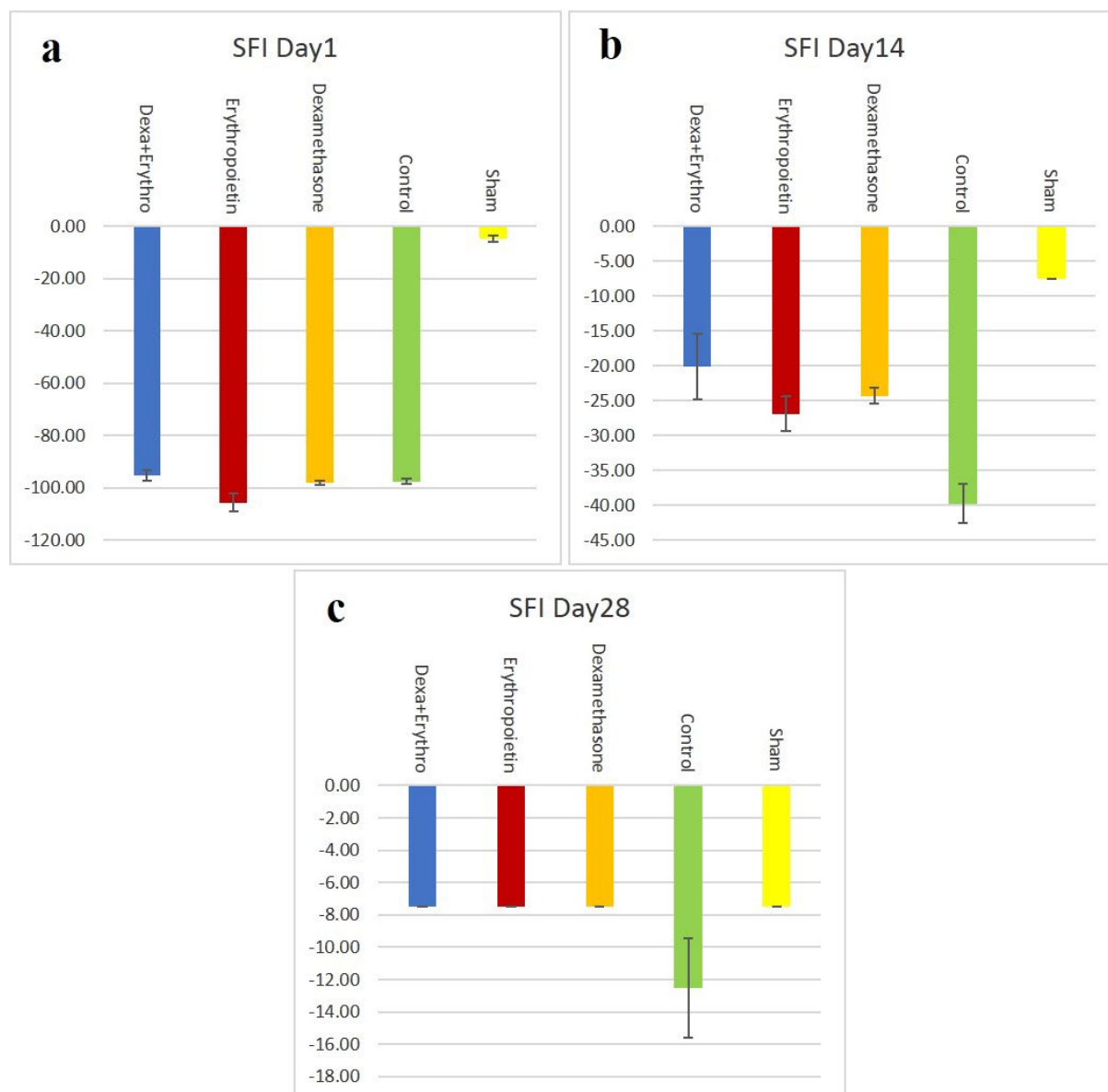


Figure 1 – Bar graph indicating the effects of medications on the sciatic functional index (SFI) on days 1(a), 14 (b), and 28 (c) after surgery. Data are presented as Mean \pm SD ($p < 0.05$).

SFI values for the sham group were near zero at all-time points. There was no significant difference between the SFI values of the sham group on both days 14 and 28 compared to day 1 ($p = 0.077$), verifying the validity of the study (Figure 1a, 1b and 1c).

Based on repeated measures with a 95% confidence interval, SFI values of the control group were significantly different from the day 1 values in the measured time points ($p = 0.011$ and $p = 0.001$ for days 14 and 28 respectively) (Figures 1a, 1b and 1c). SFI values were significantly different on both days 14 and 28 in comparison to the day 1 values both in the dexamethasone group and erythropoietin group ($p \leq 0.001$). Additionally, in the dexamethasone + erythropoietin group SFI values on day 1 were significantly different from the SFI values on day 14 ($p = 0.004$) and day 28 ($p < 0.01$) (Figure 1a, 1b and 1c).

Preoperatively the SFI values in mice were measured at approximately -7.5, which represents normal function. After the surgery, SFI decreased dramatically to values around -100, indicating a complete loss of function. According to the one-way ANOVA test, a statistically significant difference was present between groups on day 14. At this time point, SFI values returned to -39.76 ± 2.80 , -24.30 ± 1.08 , -26.90 ± 2.49 , -20.13 ± 4.74 , in the control, dexamethasone, erythropoietin, and dexamethasone + erythropoietin groups respectively (Table 1, Figure 1b).

Groups	Day 0	Day 1	Day 14	Day 28
Sham		-4.77 ± 1.37	-7.50 ± 0.00	-7.50 ± 0.00
Control		-97.54 ± 0.94	-39.76 ± 2.80	-12.52 ± 3.08
Dexamethasone	-5.61 ± 0.00	-98.08 ± 0.73	-24.30 ± 1.08	-7.50 ± 0.00
Erythropoietin		-105.71 ± 3.47	-26.90 ± 2.49	-7.50 ± 0.00
Dexamethasone + Erythropoietin		-95.15 ± 1.95	-20.13 ± 4.74	-7.50 ± 0.00

Table 1 – SFI descriptive statistics described by Mean ± SEM.

Although, intragroup assessment by means of LSD post hoc analysis demonstrated no statistically significant difference among the various medication groups on day 14 ($p > 0.05$), the difference between the control and all medication groups were significant ($p = 0.001$, $p = 0.006$, $p < 0.001$ for dexamethasone, erythropoietin and dexamethasone + erythropoietin groups respectively). After 28 days, SFI values were returned to -7.5 ± 0 and -12.52 ± 3.08 in the experimental groups and the control group respectively (Table 1, Figure 1c). No statistically significant difference was found between groups based on the one-way ANOVA test at this time point.

3.2. Histopathologic observations

Four indices (perineurium development, axonal swelling, leukocyte infiltration, and axon loss) were defined from the histopathologic prospect. Each group received a score for these indices based on light microscopy examination of hematoxylin-eosin staining (Table 2, Figures 2 and 3) and toluidine blue staining (Figure 4) on day 28.

Table 2. Scores for defined histopathological indices in each group based on light microscopy evidence in H&E and Toluidine blue-stained slides

Index	Evaluation scale	Score	Groups				
			Sham	Control	Dexamethasone	Erythropoietin	Dexamethasone + Erythropoietin
Perineurium formation	Lack of formation	0					
	Less than 25%	1					
	Between 25-50%	2	4	4	4	4	4
	Between 50-75%	3					
Leukocyte infiltration*	Complete formation	4					
	Marked	0					
	Moderate	1					
	Mild	2	4	2	3	3	3
Axonal Swelling*	Minimal	3					
	Lack of infiltration	4					
	Marked	0					
	Moderate	1					
Average axonal number	Mild	2	4	1	1	3	3
	Minimal	3					
	No swelling	4					
	25% normal nerve	1					
Summation	50% normal nerve	2	4	2	2	3	3
	75% normal nerve	3					
	Similar to normal nerve	4					
		16	16	9	10	13	13

*Marked: more than 75%, Moderate: between 50-75%, Mild: between 50-75%, Minimal: less than 25%

Table 2 – Scores for defined histopathological indices in each group based on light microscopy evidence in H&E and Toluidine blue-stained slides.

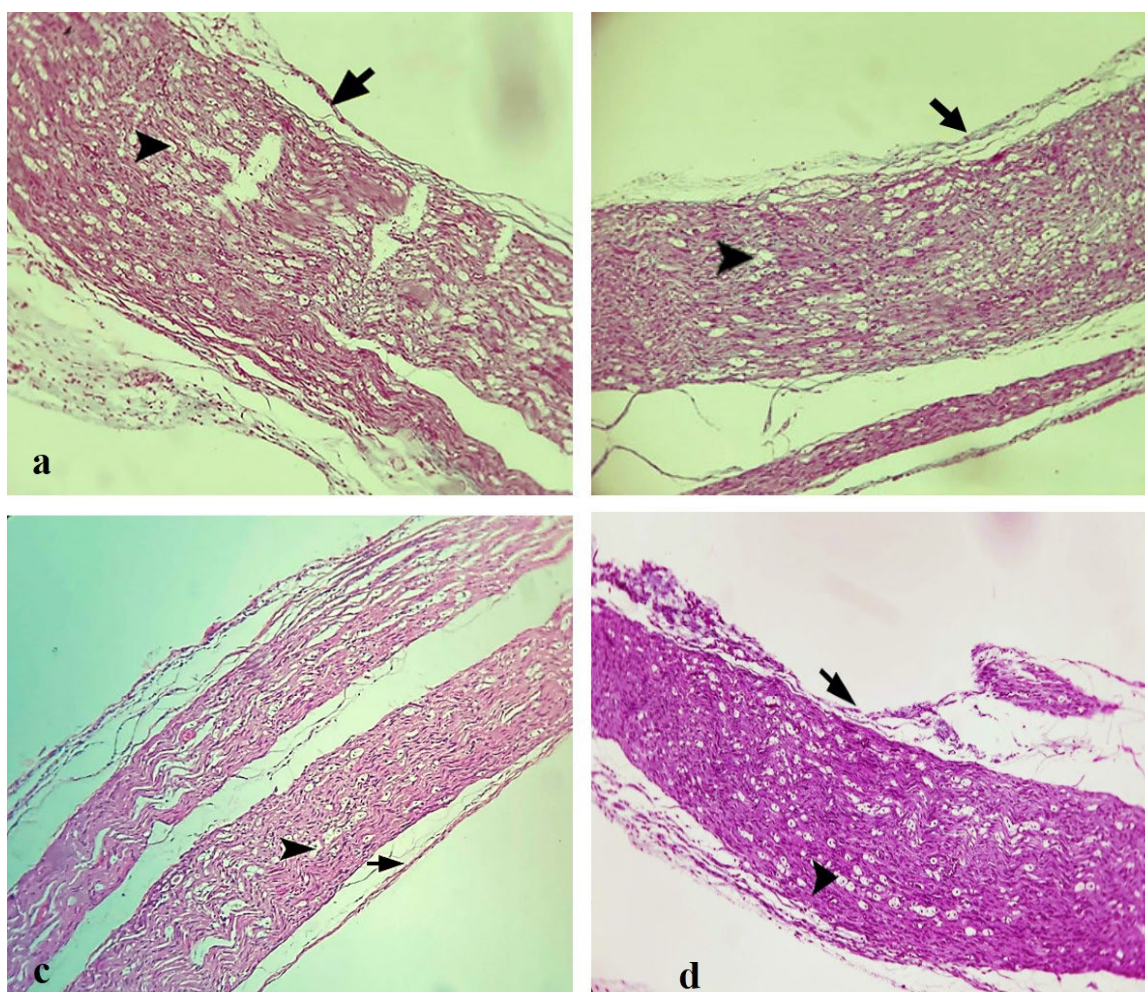


Figure 2 – Histological analysis of mice sciatic nerve on day 28 after surgery in the control (a), dexamethasone (b), erythropoietin (c), and dexamethasone + erythropoietin (d). The arrow indicates complete perineurium formation and the arrowhead depicts axonal swelling (vacuolization).

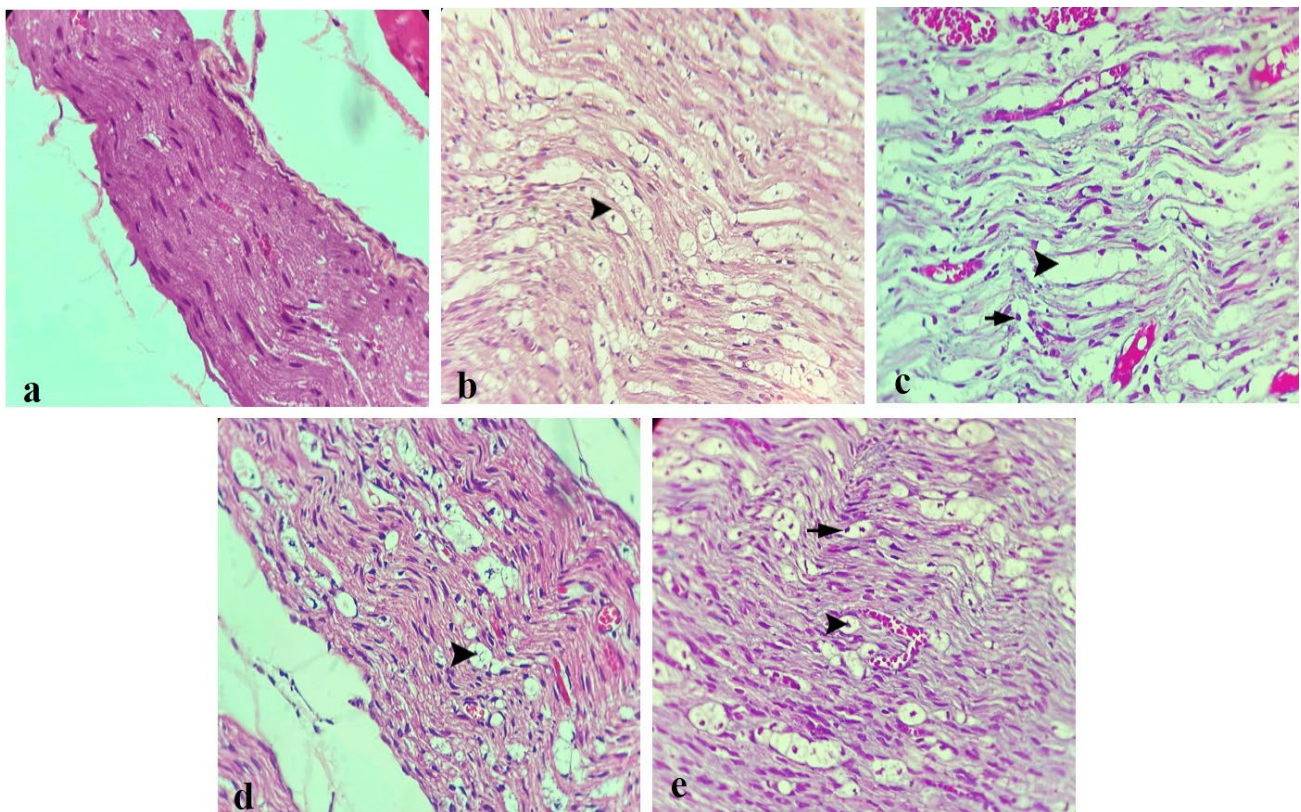


Figure 3 – Histological analysis of the sciatic nerve on day 28 after surgery in the sham (a), control (b), dexamethasone (c), erythropoietin (d), and dexamethasone + erythropoietin (e) groups (H&E staining, 40X). (a) Normal nerve structure in the sham group. (b), (c), (d), and (e) Vacuolization of the nerve tissue indicative of axonal swelling (arrowhead), and inflammatory cell infiltration (arrow) have been shown.

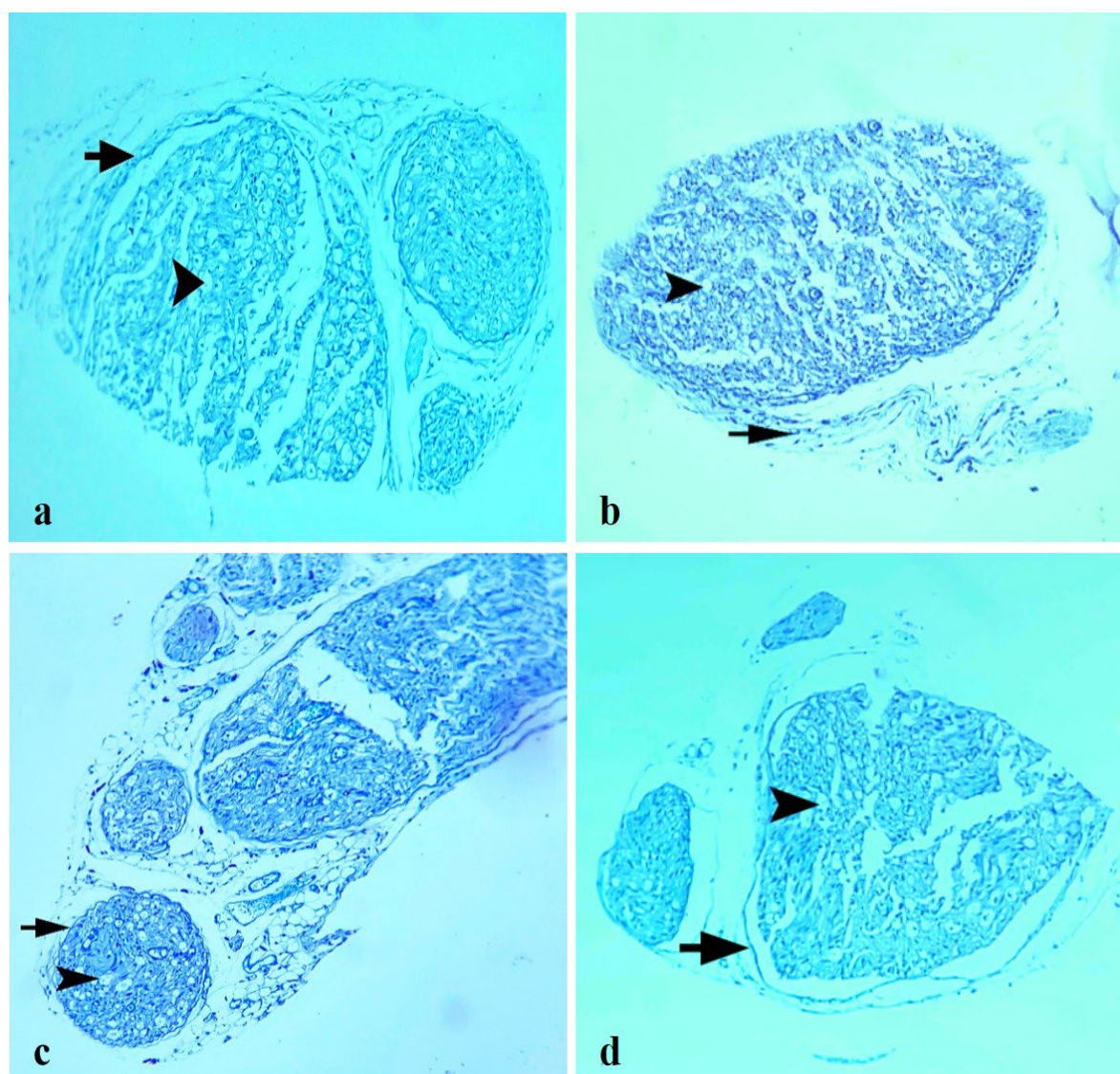


Figure 4 – Histological analysis of the sciatic nerve on day 28 after surgery in the control (a), dexamethasone (b), erythropoietin (c), and dexamethasone + erythropoietin (d) groups (Toluidine blue staining, 10X). Vacuolization of the nerve tissue indicative of axonal swelling (arrowhead), and complete perineurium formation (arrow) have been shown.

All groups showed complete perineurium formation (score 4) (Table 2, Figures 2 and 4). Based on the Kruskal-Wallis analysis, there was no statistically significant difference regarding the perineurium formation index among any of the 5 groups ($p = 1$).

Concerning leukocyte infiltration, no inflammatory cells were present in the sham group (score 4) (Figure 2a). Inflammatory cell infiltration was mild (score 2) in the control group. Minimal inflammatory cell infiltration (score 3) was seen in the dexamethasone and dexamethasone + erythropoietin groups (Table 2, Figure 2 a-d). Inflammatory cell infiltration was significantly different among the 5 groups according to the Kruskal-Wallis test ($p < 0.001$). The Mann-Whitney U test showed significantly different inflammatory cell infiltration between the sham and other groups ($p = 0.036$). Furthermore, a significant difference was noted regarding this index between the control and experimental groups ($p = 0.008$). No statistically significant difference was present between the dexamethasone and erythropoietin groups ($p = 1$). In addition, no significant difference was found between the dexamethasone + erythropoietin and either of the drugs individually ($p = 1$).

Comparing axonal swelling between different groups by means of the Kruskal-Wallis test demonstrated a significant statistical difference ($p < 0.001$). None of the groups showed marked swelling (score 0). There was no axonal swelling (score 4) in the sham group. The greatest amount of axonal swelling (score 1) among experimental groups was

attributed to the dexamethasone group which was similar to the control group. The degree of swelling was minimal (score 3) in both erythropoietin and dexamethasone + erythropoietin groups (Table 2). Arrowhead depicts axonal swelling in Figures 2, 3 and 4.

According to the Mann-Whitney U test, axonal swelling was significantly lower in the sham group compared to the control and all experimental groups ($p = 0.03$). Axonal swelling wasn't significantly different between the control and dexamethasone groups ($p = 1$). However, axonal swelling was significantly higher in the dexamethasone group compared to both erythropoietin and dexamethasone + erythropoietin groups ($p = 0.008$). Swelling was significantly lower in both erythropoietin and dexamethasone + erythropoietin groups relative to the control group ($p = 0.008$). In addition, no significant difference was noted regarding this index between erythropoietin and dexamethasone + erythropoietin groups ($p = 1$).

Average axonal recovery was the same as the normal nerve in the sham group (score 4). The dexamethasone group showed the same recovery as the control group (50% normal nerve). The average axonal recovery was up to 75% normal nerve in the erythropoietin and dexamethasone + erythropoietin groups (Table 2). Intergroup assessment via the Kruskal-Wallis test showed a significant difference regarding the average axonal recovery ($p < 0.001$). Based on the Mann-Whitney U test, a significant difference was present between sham and other groups ($p = 0.036$). Moreover, there was a significant difference regarding axonal recovery among the control and all experimental groups ($p = 0.008$) except for the dexamethasone group ($p = 1$). The average axonal recovery wasn't significantly different between erythropoietin and dexamethasone + erythropoietin groups ($p = 1$), while, both groups exhibited significantly higher average axonal recovery relative to the dexamethasone alone ($p = 0.008$).

3.3. Immunohistochemistry

Table 3 represents immunoreactivity to GFAP and S-100 markers in different groups. No immunoreactivity to GFAP was found in the sham group (Figure 5a). Moderate GFAP immunoreactivity (++) was found in the control group. In addition, marked immunoreactivity (+++) was observed in the dexamethasone group. Moderate immunoreactivity (++) was noted in both erythropoietin and dexamethasone + erythropoietin groups (Figure 5b-e).

Immunoreactivity to S-100 protein was also observed in the regenerated nerves in all groups (Figure 6). S-100 protein expression was as follows: moderate cytoplasmic staining (++) in the sham group, marked cytoplasmic staining (+++) in the control and dexamethasone groups, moderate cytoplasmic staining (++) in the erythropoietin, and dexamethasone + erythropoietin groups (Figure 6 a-e).

Group	S-100	GFAP
Sham	++	–
Control	+++	++
Dexamethasone	+++	+++
Erythropoietin	++	++
Dexamethasone and Erythropoietin	++	++

Table 3 – Immunohistochemistry stains intensity in each group.

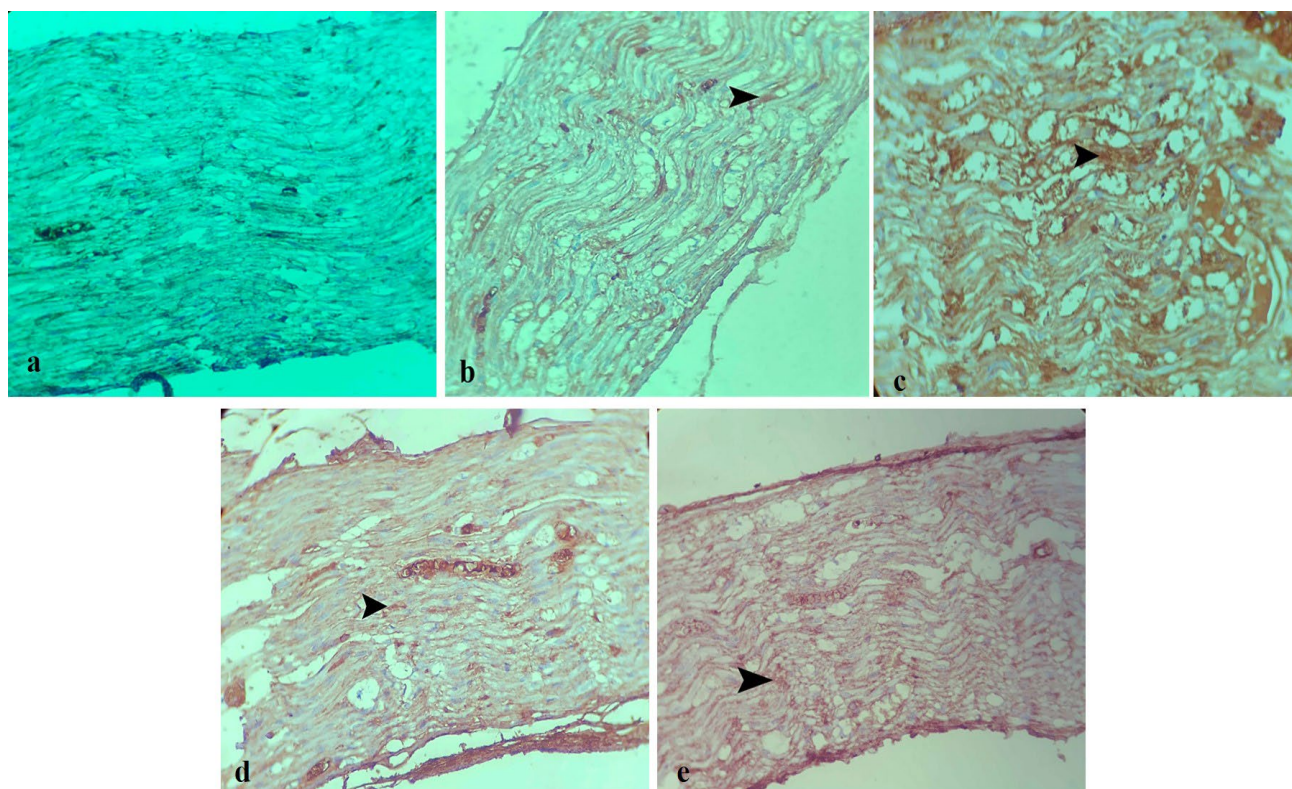


Figure 5 – Immunohistochemical staining (GFAP) of mice sciatic nerve sections on day 28 after surgery (IHC, 40X). Lack of GFAP expression in the sham group (a). Arrowhead depicts GFAP expression in the control group (b), dexamethasone group (c), erythropoietin group (d), and dexamethasone + erythropoietin (e) group.

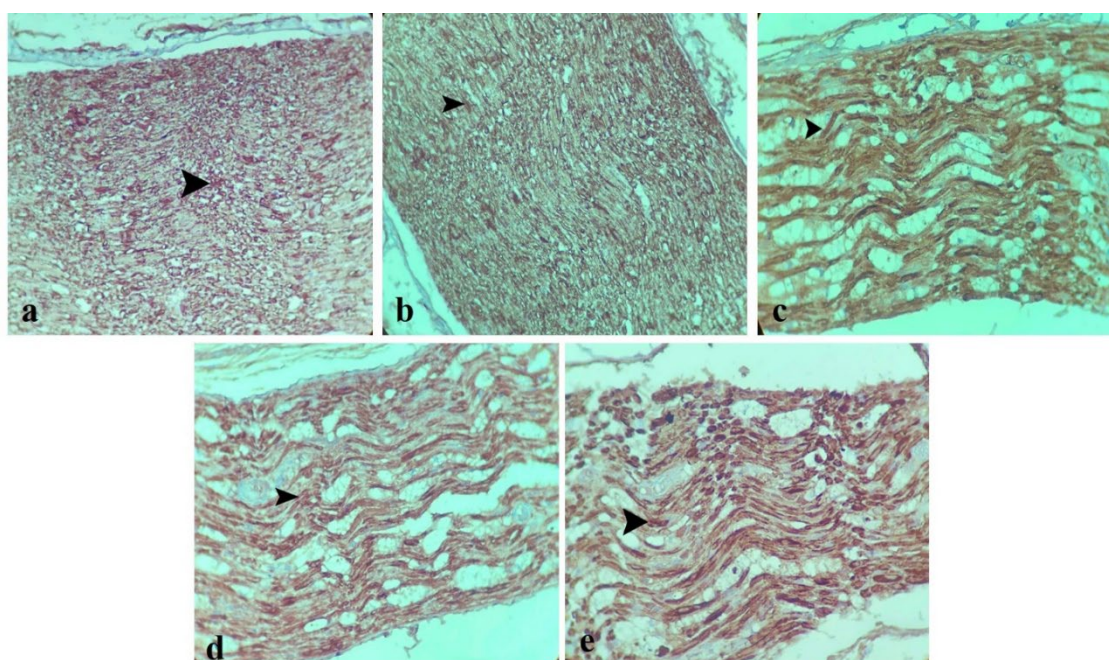


Figure 6 – Immunohistochemical staining (S-100) of mice sciatic nerve on day 28 after surgery. (a) Arrowhead depicts S-100 expression in the sham group (a) (IHC, 10X), control group (b) (IHC, 10X), dexamethasone group (c), erythropoietin group (d), and Dexamethasone + erythropoietin group (e) (IHC, 40X).

3.4. Gross observations

No sign of self-mutilation was observed. Neither surgical site infection nor inflammatory reaction was present in any of the animals. Complete skin and muscle fascia closure was noted in all of the animals. Muscle adhesion was marked (+++) in the sham and control groups, moderate (++) in the dexamethasone group, and weak (+) in the erythropoietin and dexamethasone + erythropoietin groups. Tissue derangement was weak (+) in both the sham and control groups, moderate (++) in the dexamethasone group, and weak (+) in the erythropoietin and dexamethasone + erythropoietin groups. No adherence of the nerve to the surrounding muscles was observed in the sham, dexamethasone, dexamethasone + erythropoietin, and erythropoietin groups. Therefore, the nerve was easily separable from the adjacent tissue. However, dissection of the nerve was slightly difficult in the control group due to weak (+) muscle-to-nerve adherence.

4. Discussion

As mentioned earlier, peripheral nerve lesions are prevalent and treatment is very challenging, therefore, peripheral nerve injury (PNI) is a pivotal health issue in the present era (Imran et al., 2019). PNI are usually not life threatening but can significantly decrease the quality of life owing to their negative consequences including intractable pain, disability, muscular atrophy, paresis/paralysis, and high medical costs (Jones, Eisenberg, and Jia, 2016; Lin et al., 2018; Panagopoulos, Megaloikonos, and Mavrogenis, 2017).

Despite major advances in our understanding of pathophysiology and treatment strategies for peripheral neuropathy, the end results of nerve repair have not reached their zenith, and only about half of the patients will regain desired function (Chen et al., 2017). Although surgical treatment of traumatized sciatic nerve is the treatment of choice, surgical repair is often limited by local inflammation and scar-tissue (Mekaj et al., 2014). Myelin and axonal degeneration, adjacent muscles atrophy and injury severity further negatively affect the outcomes of surgery (Grinsell and Keating, 2014; Panagopoulos, Megaloikonos, and Mavrogenis, 2017). Several research has evaluated topical and systemic pharmacologic agents to overcome the aforementioned problems and to accelerate regeneration process, especially in the case of crushing nerve injuries (Panagopoulos, Megaloikonos, and Mavrogenis, 2017; Feng and Yuan, 2015; Wang et al., 2015). Amongst these drugs, corticosteroids, especially dexamethasone, have attracted researchers' attention possibly due to potency, minimum adverse effects and cost-effectiveness (Sun et al., 2012; de Souza et al., 2018; Suslu et al., 2013). According to Shishido et al. (2002); dexamethasone can reduce edema and

overcome the consequences of nerve inflammation. Moreover, de Souza et al. (2018); confirmed the beneficial effects of dexamethasone and laser therapy of dexamethasone on peripheral nerve regeneration by histopathologic and immunohistochemical evaluations. Contrary to their results, anti-inflammatory benefits of dexamethasone were not confirmed in Uzun et al. study (2019); rather they only reported decreased fibrosis scores. In the present study, inflammatory cell infiltration reduction wasn't exclusive to dexamethasone since significantly lower inflammatory cell infiltration was observed in all of the medication groups compared to the control group. In addition, the greatest amount of axonal swelling was seen in the dexamethasone group which was equivalent to the control group (Table 2). Therefore, in line with Uzun et al. (2019); we didn't confirm anti-inflammatory effects of dexamethasone by histopathologic evaluation.

Another drug with a noteworthy role in peripheral nerve regeneration is erythropoietin which has been used to treat patients suffering anemia since 1990 (Elfar et al., 2008). Recently erythropoietin's neurotrophic and neuroprotective characteristics were identified (Wang et al., 2015; Campana and Myers, 2001; Zhang et al., 2015). Erythropoietin enhances axonal regrowth and attenuates inflammation. It also plays a strong anti-apoptotic role, protects tissues from ischemia and oxidative radicals, and encourages healing by directly stimulating protective molecules (Elfar et al., 2008; Geary et al., 2017; Yin et al., 2010). In addition, erythropoietin promoted peripheral nerve regeneration by up-regulating the expression of insulin-like growth factor-1 (Wang et al., 2015). Moreover, erythropoietin has been suggested to have a direct and local effect on myelination *in vivo* so that it protects myelin and promotes myelin formation (Sundem et al., 2016).

In the present study erythropoietin induced significant axonal recovery compared to the control group. Average axonal recovery was significantly higher in both erythropoietin and dexamethasone + erythropoietin groups compared to the dexamethasone group. Furthermore, erythropoietin reduced axonal swelling significantly compared to the dexamethasone. Therefore, it may be inferred that erythropoietin potentiates axonal number recovery. The greatest amount of axonal swelling in the dexamethasone group together with superior reduction of swelling in groups treated by erythropoietin may suggest erythropoietin positive role in the prevention or suppression of the axonal swelling. Dexamethasone either has no such influence in decreasing axonal swelling or possibly induces tissue reactions that exacerbate swelling in the regeneration process.

A clear correlation has been shown between sciatic functional index and morphologic and morphometric evaluation of the nerve. SFI provides an opportunity to evaluate nerve regeneration non-invasively and obtains a numerical value which allows statistical analysis of functional recovery (de Souza et al., 2018; Mohammadi, Azad-Tirgan, and, Amini, 2013; de Medinaceli, Freed, and Wyatt, 1982). The effects of glucocorticoids on the nerve function were first evaluated in 1982. Triamcinolone reported to be effective in functional recovery of the severed monkey's median nerve after immediate repair in this study (seth et al., 2012). Further, Suslu et al. (2013); compared systemic and local administration of dexamethasone after sciatic nerve crush. SFI records were better in dexamethasone receiving groups compared to the control group regardless of the route. In addition, Galloway et al. showed more rapid sciatic functional recovery by topically applied dexamethasone on postoperative days 14, 18 and 21, and this reached statistical significance on day 14 (Suslu et al., 2013). In line with them, we observed significantly better SFI values in dexamethasone-treated animals compared to saline-treated ones on day 14 ($p = 0.001$). This may suggest that dexamethasone has positive influence on functional recovery in as soon as 14 days. Moreover, dexamethasone yielded superior SFI values compared to erythropoietin at this time point, although this was not statistically significant ($p = 0.534$) (Table 1, Figure 1b).

Concerning erythropoietin role in enhancing functional recovery, Elfar et al. (2008); reported accelerated functional recovery using single dose of systemic erythropoietin subsequent to sciatic nerve crush injury regardless of the timing of administration. Moreover, Geary et al. (2017); stated that erythropoietin has capacity to induce functional recovery subsequent to moderate sciatic nerve crush. Present data demonstrated statistically significant functional recovery in the erythropoietin group compared to the control group on day 14 ($p = 0.006$).

In terms of dexamethasone immunohistochemical influences, a study by Feng and Yuan (2015); provided strong evidence that intramuscular injection of dexamethasone decreased the number of CD3-positive cells and enhanced the expression of growth-associated protein 43 (GAP-43). Furthermore, Sun et al. (2012); suggested that combining dexamethasone and vitamin B₁₂ could promote sciatic nerve regeneration by up-regulation of brain derived neurotrophic factor (BDNF). In the present study, immunohistochemical evaluation demonstrated marked (+++) expression of S-100 in the dexamethasone group. We also examined GFAP expression, a very useful marker of glial cells in the central and peripheral nervous systems. In this regard, although at least moderate GFAP expression was seen in the control,

erythropoietin and dexamethasone/erythropoietin groups (Table 3, Figures 3b, 3d and 3e), GFAP expression was marked in the dexamethasone group (Table 3, Figure 3c).

The presence of synergistic interaction between corticosteroids and erythropoietin on nerve regeneration is questionable and findings are controversial. For instance, Gorio et al. (2005); indicated that methylprednisolone antagonized the beneficial effects of erythropoietin in the contusive spinal cord injury. Furthermore, a retrospective study by Bernstein et al. (2016); found that combining erythropoietin and oral tapered corticosteroids accelerates the recovery of motor and sensory function after joint replacement arthroplasty. Recently, Lee et al. (2020), showed significantly better SFI values in sole dexamethasone or erythropoietin groups relative to the control group 28 days after crush injury while the combination significantly improved SFI values compared to saline on days 3, 7 and 14, 28 suggesting accelerated functional recovery via synergistic effects. Contrary to their results, we concluded that SFI values of both dexamethasone, erythropoietin, and their combination reached significant differences compared to saline on day 14 and not on day 28. Significant better functional recovery in groups treated with medication compared to the control group ($p = 0.001$ for dexamethasone, $p = 0.006$ for erythropoietin and $p < 0.001$ for dexamethasone + erythropoietin) may suggest that medical therapy promotes the recovery of SFI in the injured sciatic nerve.

In agreement with Lee et al. (2020) regarding synergistic effects between dexamethasone and erythropoietin, present data showed higher SFI values thus, better functional recovery in the dexamethasone + erythropoietin group (Table. 1, Figure 1b) compared to either of the drugs alone. This may imply a possible synergistic effect of dexamethasone + erythropoietin, although this wasn't proved statistically significant ($p = 0.321$ for dexamethasone and $p = 0.115$ for erythropoietin).

In the present study, we assessed dexamethasone, erythropoietin and their simultaneous administration from the histopathologic point of view as well. Monotherapy with each drug and also administration of both drugs reduced inflammatory cell infiltration significantly relative to the control group ($p = 0.008$). In addition, simultaneous administration of dexamethasone and erythropoietin reduced axonal swelling significantly compared to both the control and dexamethasone groups ($p = 0.008$). Furthermore, axons recovered up to 75% normal in the dexamethasone + erythropoietin group which was significantly higher than the axonal number recovery compared to dexamethasone solely ($p = 0.008$). The latter combined with significantly higher average axonal recovery in the erythropoietin group compared to the dexamethasone group ($p = 0.008$) and also absence of significant difference regarding axonal count between the control and dexamethasone groups ($p = 1$) may suggest erythropoietin's role in potentiating axonal count recovery.

5. Conclusions

Altogether, the results of the present study provide encouraging insights into the neuroprotective and neurotrophic effects of dexamethasone and erythropoietin. Dexamethasone and erythropoietin each yielded promising results in nerve regeneration from the histopathologic point of view. In addition, dexamethasone and erythropoietin together induced better functional recovery although this was not statistically confirmed. Not enough data was achieved to statistically support clear synergistic effects of dexamethasone and erythropoietin by the sample, dose, route, and duration used in this study. Whether actual synergism exists and verifying their possible synergistic advantages requires further trials. Given the almost maximum effect of medications on functional recovery on day 14 and complete return to near normal function in 28 days it may be inferred that the study time point was too long for assessing sciatic nerve crush injury because 28 days was sufficient for the sciatic nerve crush injury to heal regardless of the drug applied. The authors believe that better results would be achieved in medication groups if functional studies were done earlier in the course of the study.

Informational note: The experimental design and protocols were approved by the Research Ethics Committees of Islamic Azad University- Science and Research Branch on 16/6/2021 (approval ID IR.IAU.SRB.REC.1400.024).

6. References

- Araújo-Filho HG, Quintans-Júnior LJ, Barreto AS, Almeida JR, Barreto RS, Quintans JS. Neuroprotective Effect of Natural Products on Peripheral Nerve Degeneration: A Systematic Review. *Neurochem Res.*, 41:(4);647-58, 2016.
- Bernstein DT, Weiner BK, Tasciotti E, Mathis KB. Does the combination of erythropoietin and tapered oral corticosteroids improve recovery following iatrogenic nerve injury? *Injury.*, 47:(8); 1819-23, 2016.
- Campana WM, Myers RR. Erythropoietin and erythropoietin receptors in the peripheral nervous system: changes after nerve injury. *FASEB J.*, 15:(10);1804-6, 2001.
- Chen MM, Qin J, Chen SJ, Yao LM, Zhang LY, Yin ZQ, Liao H. Quercetin promotes motor and sensory function

- recovery following sciatic nerve-crush injury in C57BL/6J mice. *J Nutr Biochem.*, 46;57-67, 2017.
- Diem R, Sättler MB, Merkler D, Demmer I, Maier K, Stadelmann C, Ehrenreich H, Bähr M. Combined therapy with methylprednisolone and erythropoietin in a model of multiple sclerosis. *Brain.*, 128;(Pt2);375-85, 2005.
- de Souza LG, Marcolino AM, Kuriki HU, Gonçalves ECD, Fonseca MCR, Barbosa RI. Comparative effect of photobiomodulation associated with dexamethasone after sciatic nerve injury model. *Lasers Med Sci.*, 33;(6);1341-1349, 2018.
- de Medinaceli L, Freed WJ, Wyatt RJ. An index of the functional condition of rat sciatic nerve based on measurements made from walking tracks. *Exp Neurol.*, 77;(3);634-643, 1982.
- Elfar JC, Jacobson JA, Puzas JE, Rosier RN, Zuscik MJ. Erythropoietin accelerates functional recovery after peripheral nerve injury. *J Bone Joint Surg Am.*; 90;(8);1644-53, 2008.
- Feng X, Yuan W. Dexamethasone enhanced functional recovery after sciatic nerve crush injury in rats. *Biomed Res Int.*, 2015;627923, 2015.
- Geary MB, Li H, Zingman A, Ketz J, Zuscik M, De Mesy Bentely KL, Noble M, Elfar JC. Erythropoietin accelerates functional recovery after moderate sciatic nerve crush injury. *Muscle Nerve.*, 56 : (1);143-151, 2017.
- Gorio A, Madaschi L, Di Stefano B, Carelli S, Di Giulio AM, De Biasi S, Coleman T, Cerami A, Brines M. Methylprednisolone neutralizes the beneficial effects of erythropoietin in experimental spinal cord injury. *Proc Natl Acad Sci U S A.*, 102;(45);16379-84, 2005.
- Grinsell D, Keating CP. Peripheral nerve reconstruction after injury: a review of clinical and experimental therapies. *Biomed Res Int.*, 2014;698256, 2014.
- Imran A, Xiao L, Ahmad W, Anwar H, Rasul A, Imran M, Aziz N, Razzaq A, Arshad MU, Shabbir A, Gonzalez de Aguilar JL, Sun T, Hussain G. Foeniculum vulgare (Fennel) promotes functional recovery and ameliorates oxidative stress following a lesion to the sciatic nerve in mouse model. *J Food Biochem.*, 43;(9);e12983, 2019.
- Inserra MM, Bloch DA, Terris DJ. Functional indices for sciatic, peroneal, and posterior tibial nerve lesions in the mouse. *Microsurgery.*, 18;(2);119-24, 1998.
- Jang CH, Cho YB, Choi CH, Jang YS, Jung WK. Effect of topical dexamethasone in reducing dysfunction after facial nerve crush injury in the rat. *Int J Pediatr Otorhinolaryngol.*, 78;(6);960-3, 2014.
- Jones S, Eisenberg HM, Jia X. Advances and Future Applications of Augmented Peripheral Nerve Regeneration. *Int J Mol Sci.*, 17;(9);1494, 2016.
- Lee JI, Hur JM, You J, Lee DH. Functional recovery with histomorphometric analysis of nerves and muscles after combination treatment with erythropoietin and dexamethasone in acute peripheral nerve injury. *PLoS one.*, 15;(9);e0238208, 2020.
- Lin T, Qiu S, Yan L, Zhu S, Zheng C, Zhu Q, Liu X. Miconazole enhances nerve regeneration and functional recovery after sciatic nerve crush injury. *Muscle Nerve.*, 57;(5); 821-828, 2018.
- Mekaj AY, Morina AA, Bytyqi CI, Mekaj YH, Duci SB. Application of topical pharmacological agents at the site of peripheral nerve injury and methods used for evaluating the success of the regenerative process. *J Orthop Surg Res.*, 9;(94), 2014.
- Mohammadi R, Azad-Tirgan M, Amini K. Dexamethasone topically accelerates peripheral nerve repair and target organ reinnervation: a transected sciatic nerve model in rat. *Injury.*, 44 : (4);565-9, 2013.7.
- Panagopoulos GN, Megaloikonomos PD, Mavrogenis AF. The Present and Future for Peripheral Nerve Regeneration. *Orthopedics.*, 40;(1);e141-e156, 2017.
- Seth R, Revenaugh PC, Kaltenbach JA, Rajasekaran K, Meltzer NE et al. Facial nerve neurotomy and the effects of glucocorticoids in a rat model. *Otolaryngol Head Neck Surg.*, 47;(5);832-40, 2012.
- Shishido H, Kikuchi SH, Heckman H, Myers RR. Dexamethasone decreases blood flow in normal nerves and dorsal root ganglia. *Spine (Phila Pa 1976).*, 27;(6);581-6, 2002.
- Sun H, Yang T, Li Q, Zhu Z, Wang L, Bai G, Li D, Li Q, Wang W. Dexamethasone and vitamin B (12) synergistically promote peripheral nerve regeneration in rats by upregulating the expression of brain-derived neurotrophic factor. *Arch Med Sci.*, 8;(5);924-30, 2012.
- Sundem L, Chris Tseng KC, Li H, Ketz J, Noble M, Elfar J. Erythropoietin Enhanced Recovery After Traumatic Nerve Injury: Myelination and Localized Effects. *J Hand Surg Am.*, 41;(10); 999-1010, 2016.
- Suslu H, Altun M, Erdivanli B, Turan Suslu H. Comparison of the effects of local and systemic dexamethasone on the rat traumatic sciatic nerve model. *Turk Neurosurg.*, 23;(5);623-9, 2013.
- Uzun T, Toptas O, Saylan A, Carver H, Turkoglu SA. Evaluation and Comparison of the Effects of Artesunate, Dexamethasone, and Tacrolimus on Sciatic Nerve Regeneration. *J Oral Maxillofac Surg.*, 77;(5);1092.e1-1092.e12, 2019.
- Wang PH, Tsai CL, Wu KC, Shao CJ, Kuo LC, Jou IM. Effects of different dosage of dexamethasone on behavioral, electrophysiological, and histomorphological recovery in a chronic sciatic nerve compression model. *Pain Med.*, 16;(4);765-76, 2015.
- Wang W, Li D, Li Q, Wang L, Bai G, Yang T, Li Q, Zhu z, Sun H. Erythropoietin promotes peripheral nerve regeneration in rats by upregulating expression of insulin-like growth factor-I. *Arch Med Sci.*, 11;(2);433-7, 2015.
- Yin ZS, Zhang H, Bo W, Gao W. Erythropoietin promotes functional recovery and enhances nerve regeneration after peripheral nerve injury in rats. *AJNR Am J Neuroradiol.*, 31;(3); 509-15, 2010.
- Yüce S, Cemal Gökçe E, İşkdemir A, Koç ER, Cemil DB, Gökçe A, Sargon MF. An experimental comparison of the effects of propolis, curcumin, and methylprednisolone on crush injuries of the sciatic nerve. *Ann Plast Surg.*, 74;(6);684-92, 2015.

- Zamani N, Hassanian-Moghadam H, Shojaei M, Rahimian S. Evaluation of the effect of erythropoietin + corticosteroid versus corticosteroid alone in methanol-induced optic nerve neuropathy. *Cutan Ocul Toxicol.*, 37:(2);186-190, 2018.
- Zhang W, Gao Y, Zhou Y, Liu J, Zhang L, Long A, Zhang L, Tang P. Localized and sustained delivery of erythropoietin from PLGA microspheres promotes functional recovery and nerve regeneration in peripheral nerve injury. *Biomed Res Int.*, 2015; 478103, 2015.