

**LAMINITIS IN CULLED SOWS FROM COMMERCIAL SWINE FARMS OF SOUTHERN BRAZIL**

*Laminite em porcas descartadas provenientes de granjas comerciais de suínos do sul do Brasil*

GUIMARAES, A.M.S.<sup>1</sup>; ALTHAUS, L.K.<sup>1</sup>; TULLIO, D.M.<sup>1</sup>; DECONTO, I.<sup>1</sup>; SILVA, A.W.<sup>1</sup>; FERRARI, M.V.<sup>1</sup>; BIONDO, A.W.<sup>1</sup>; ALBERTON, G.C.<sup>1</sup>

<sup>1</sup> Departamento de Medicina Veterinária - UFPR . E-mail address: alberton@ufpr.br (G. C. Alberton)

**ABSTRACT**

Although laminitis has been reported in pigs, distal phalanx rotation detected by radiography has not been described yet in this species. Accordingly, this paper describes three cases of laminitis in sows from a Brazilian commercial swine unit, and a preliminary study on laminitis in culled sows from a slaughterhouse, based on radiographic evaluation. A farrow-to-finish unit located in a central swine production area in southern Brazil showed a history of locomotor alterations in sows. Three lame sows were selected for examination. They presented typical clinical signs of laminitis. Their feet were radiographed, and all three showed distal phalanx deviation in at least one digit. To address the possibility of existing laminitis in other farms, thirteen hind and five front feet from lame sows were collected in a slaughterhouse, and radiographed in lateromedial position. Eleven sows (61%) showed distal phalanx rotation of the third or the fourth digit, whereas eight of them (44%) showed this alteration in both digits. Osteolysis in five sows (28%) and periosteal proliferation in another four sows (11%) were observed. In conclusion, laminitis with distal phalanx rotation is present in Brazilian herds, and radiographic analysis may be an important diagnosis tool for the disease *in vivo* or at slaughterhouses.

**Key words:** laminitis, rotation, phalanx, lameness, pigs.

**RESUMO**

Embora a laminite tenha sido relatada em suínos, a rotação de falange distal detectada por radiografia ainda não foi descrita nessa espécie. O presente trabalho descreve três casos de laminite em porcas provenientes de uma granja comercial de suínos bem como relata um estudo preliminar sobre laminite em porcas de descarte em abatedouro, baseado em avaliações radiográficas. Uma granja de ciclo completo localizada em uma área de exploração suinícola do sul do Brasil mostrou histórico de alterações locomotoras em porcas. Três porcas com claudicação foram selecionadas para exame. Elas apresentavam sinais clínicos típicos de laminite. Seus membros foram radiografados e todas apresentaram rotação de falange distal em pelo menos um dígito. Para verificar a presença de laminite em outros rebanhos da região, treze membros pélvicos e cinco membros torácicos de matrizes suínas foram colhidos em um abatedouro e radiografados em posição latero-medial. Onze porcas (61%) mostraram rotação de falange distal no terceiro ou no quarto dígito, enquanto oito delas (44%) mostraram essa alteração em ambos os dígitos. Foram observadas osteólises em cinco (28%) porcas e proliferação periosteal em quatro porcas (11%). Em conclusão, a laminite está presente em rebanhos suínos brasileiros, e a análise radiográfica constitui-se em uma importante ferramenta para o diagnóstico da doença *in vivo* ou em abatedouros.

**Palavras-chave:** laminite, rotação, falange, claudicação, suínos.

## INTRODUCTION

Locomotor disorders have been reported as causes of underproduction and culling of sows (Kirk et al., 2005; Dewey, 1999). Although fractures, osteochondrosis, osteoarthritis, and claw lesions have been associated to lameness in pigs (Dewey, 1999), laminitis has been occasionally reported (Osborne, 1950; Nilsson, 1964; Maclean, 1968; Bollwahn and Hertrampf, 1976; Dewey, 1999) and is said to be rare in Brazilian swine production (Sobestiansky et al., 1999). Laminitis is a disease characterized by low capillary perfusion of the hoof, with artery venous embezzlement, ischemic necrosis of the hoof lamellae, and pain (Barcellos, 2007).

Chronic laminitis may initiate with corium inflammation and lamellar basement membrane degeneration, thus disrupting the union between the hoof wall and the phalanx (Riedesel, 2002; Weaver et al., 2005). Distal phalanx may fail to maintain its attachment to the lamellae and rotates within the hoof in a palmar direction (Riedesel, 2002). This alteration may result in lameness, pain, and claw lesions. By definition, phalangeal rotation is the deviation of a line drawn along the dorsal surfaces of the middle and distal phalanges that is caused by the rotational movement of the distal phalanx around the distal interphalangeal joint (Herthel and Hood, 1999). It is usually measured in degrees.

Nilsson (1964) reported cases of distal phalanx deviation based on *post mortem* findings without radiography. Although the knowledge of radiological findings of swine toes is essential for diagnosis and treatment of distal phalanx rotation by laminitis, this alteration has been detected only by clinical examination, necropsy, or histological procedures (Osborne, 1950; Nilsson, 1964; Maclean, 1968). Distal phalanx rotation by laminitis in sows based on radiological evaluation has not been described to date. Thus, the objective of this case report was to describe

three clinical cases of laminitis and its complications in culled sows from a Brazilian commercial swine unit and identify the presence of chronic laminitis, represented by distal phalanx rotation, in culled sows at a slaughterhouse from Southern Brazil.

## CASE DESCRIPTION

A farrow-to-finish unit located in a central swine production area from southern Brazil displayed a history of locomotor alterations in sows. On the examination, these animals disclosed level of clinical lameness, and were maintained in loose housing and poorly laid concrete floors with non regular surfaces, and puddles of water, urine, and feces. Three lame sows (1, 2, and 3) were sent to the Veterinary Hospital of Federal University of Paraná for feet radiography and clinical examination. They were maintained in individual housing, with *ad libitum* water and food. On the examination, they presented high level of lameness, stiffed movements, and a tendency to slip. All sows showed heat and pain during feet palpation. Sow 3 displayed back arching, possibly as a result of pain, as well as fever. They were mechanically restrained for podal examination and radiographic analysis. Different sized claws, wall hemorrhages, and thickness of digital pads were observed. Lateral claws were longer than medial claws in all limbs of the three sows, and their dewclaws were regularly sized. Sow 3 showed sole erosion on the left front foot.

The radiological analysis showed periosteal proliferation of hind feet phalanges from sow 1, and distal phalanx rotation in both third and fourth digits. The left hind feet from sow 2 showed distal phalanx rotation in the fourth digit. Sow 3 had distal phalanx rotation in all the third and fourth digits.

To address the possibility of existing laminitis in other farms from the same

location, a total of thirteen hind feet and five front feet from culled lame sows from different swine units were collected in a commercial slaughterhouse located in Curitiba, Brazil. The sampling was performed prior to scalding by disarticulation of the tarsometatarsal and carpometacarpal joints. The limbs were fixed in 10% neutral buffered formalin. After sampling, the feet were longitudinally separated between the third and fourth digits, resulting in 36 podal pieces (second and third digits, and third and fourth digits, in separate). Each podal piece was submitted to lateromedial radiography using standard protocol (Riedesel, 2002).

The main observed alterations are described as follows: eleven sows (61%) showed distal phalanx rotation of the third or fourth digit (figure 1), in a total of nineteen podal pieces (52%), whereas eight of these sows (44%) showed distal phalanx rotation in both digits. Osteolysis (figure 2) was observed in the fourth digits from five sows (28%), while another four sows (11%) showed periosteal proliferation of the third, fourth, or accessory digits. Angle measurements of deviation could not be done since there are no standard procedures for pigs.

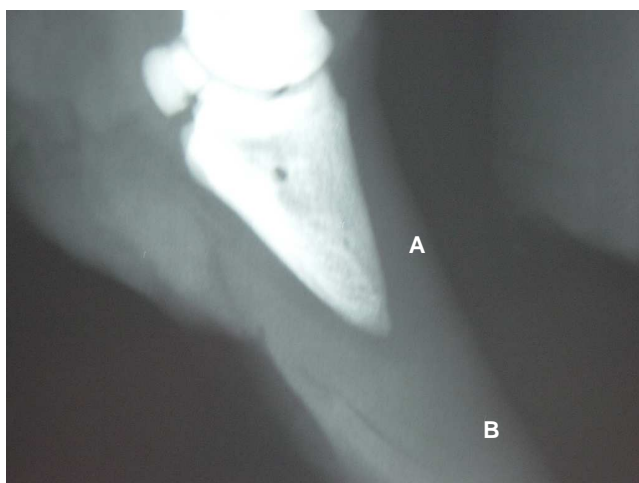

Figure 1 - Distal phalanx of third toe of a slaughterhouse culled sow. (A) phalanx deviation based on the absence of parallelism between the hoof wall and the phalanx. (B) wall horn overgrowth.

## DISCUSSION

Important findings related to radiological toes characterization were observed, despite the low number of sows' limbs analyzed. The podal pieces and the three farm sows examined in this study confirmed the presence of laminitis in Brazilian herds. Despite laminitis as an aseptic process, the fever of the sow 3 may be explained by the toe ulcer, which was suppurating at the time of the examination. The observed distal phalanx rotation may imply a chronic laminitis in these animals, as observed in horses (Riedesel, 2002).

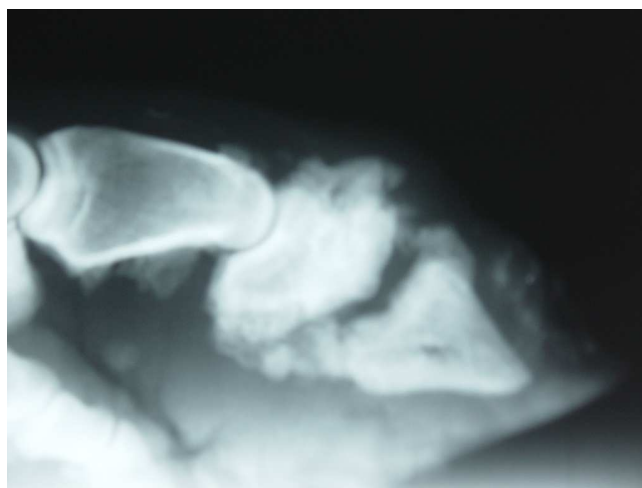


Figure 2 - Osteolysis of the forth digit of a slaughterhouse culled sow.

Similarly to cows and horses, the lame sows showed typical clinical signs of laminitis, such as pain, lameness, claw lesions, and, in particular, sole ulcers (Lischer and Ossent, 2001; Redden, 2003). Wall horn overgrowth and distal phalanx rotation may predispose to sole and toe ulcer development in bovine. In this specie, the rotation of the third phalanx may result in a pressure area in the corium between the tip of the third phalanx and the sole of the toe (Van Amstel and Shearer, 2001). This may result in a full-thickness horn defect at the toe with the formation of a toe ulcer, such as occurred with sow 3. Otherwise, the osteolysis and periosteal proliferation can be associated to infections,

chronic injury, or even as a result of laminitis (Kofler, 1999; Riedesel, 2002). Wall hemorrhages may be an effect of laminitis or of the type of floor (Lopez et al., 1997). However, in the present study it seems that non regular floor surfaces facilitated these alterations as a consequence of podal injury. Loose housing and floor moisture probably enhanced claw lesions in the farm sows (Borderas et al., 2004).

Deviation and malformation of the hoof wall may occur due to two different reasons: because of weight bearing distribution or as a consequence of laminitis. Unequal weight distribution between the claws leads to a condition in which the rate of the horn growth exceeds the rate of the wear. In this study, the thickness of the digital pad and the different size of claws suggest an imbalance on sows' weight distribution. Irregular floors, as observed in the farms, may also predispose some claw regions to overload and injury, and lateral digits are often affected in pigs (Lopez et al., 1997; Sori, 2005; Tiranti et al., 2006). In this case it is not possible to affirm if the wall horn overgrowth leads to laminitis or if it was the opposite. However, the etiology of swine laminitis is poorly understood, and given the fact that hoof wall overgrowth due to inadequate wearing is commonly observed in Brazilian swine farms, the authors believe that this alteration may have lead to distal phalanx deviation and laminitis.

The treatment description of swine laminitis was not the objective of this case report; however, it is noteworthy that the three sows from the present study were treated with consecutives claw trimmings, and antibiotics and anti-inflammatory treatments during three months. Antibiotic therapy was accomplished as prophylactic because of the trimming. During this practice, sows claws were intensely wearied, sometimes causing small injuries. In addition, the sole ulcer of the sow 3 needed to be treated with antibiotics since it

had showed signs of bacterial infection. Nevertheless, they did not recovery well, and their owner decided to cull them. Further studies should be done to establish enhanced methods for swine laminitis treatment.

## CONCLUSIONS

In this case study, detection of distal phalanx rotation by radiographic analysis was an important diagnosis tool for swine laminitis. This disease is present in Brazilian commercial swine farms, and may occur more often than previously reported. Since hoof external lesions may be a consequence of internal injuries, the authors also suggest that they should not be treated without a complete radiological examination of the phalanx conditions of the swine toe. Wall horn overgrowth due to weight distribution and wearing should be evaluated as a cause of distal phalanx rotation and laminitis.

## REFERENCES

- BARCELLOS, D. Laminite. In: SOBESTIANSKY, J.; BARCELLOS, D. **Doenças dos Suínos**. 1ed. Goiânia, Brasil: Gráfica Editora Pallotti, 2007, p. 438-439.
- BOLLWAHN, W.; HERTRAMPF, B. Laminitis and claw atrophy. In: **INTERNATIONAL PIG VETERINARY SOCIETY CONGRESS**, 4TH. 1976, Ames, Proceedings of the 4th International Pig Veterinary Society Congress. Ames: Pig Veterinary Society, 1976, p.Q3.
- BORDERAS, T.F.; PAWLUCZUK, B.; DE PASSILLE, A.M.; RUSHEN, J. Claw hardness of dairy cows: relationship to water content and claw lesions. **Journal of Dairy Science**, v. 87, n. 7, p. 2085-2093, 2004.
- DEWEY, C.E. **Diseases of the nervous and locomotor systems**. In: STRAW, B.E.; D'ALLAIRE, S.; MENGELING, W.L.; TAYLOR, D.J. Diseases of Swine. 8.ed. Ames, USA: Iowa State University Press, 1999, p. 861-882.
- HERTHEL, D.; HOOD, D.M. Clinical presentation, diagnosis, and prognosis of chronic laminitis. **Veterinary Clinics of North America Equine Practice**, v.15, n. 2, p. 375-394, 1999.

KIRK, R.K.; SVENSMARK, B.; ELLEGAARD, L.P.; JENSEN, H.E. Locomotive disorders associated with sow mortality in Danish pig herds. **Journal of veterinary medicine**. A, Physiology, pathology, clinical medicine, v. 52, n. 8, p. 423-428, 2005.

KOFLER, J. Clinical study of toe ulcer and necrosis of the apex of the distal phalanx in 53 cattle. **Veterinary Journal**, v. 157, n. 2, p. 139-147, 1999.

LISCHER, C.J.; OSSENT, P. Bovine sole ulcer: a literature review. **Berliner und Münchener tierärztliche Wochenschrift**, v. 114, n. 1-2, p. 13-21, 2001.

LOPEZ, A.C.; SOBESTIANSKY, J.; COIMBRA, J.B.S.; AFONSO, S.B. Lesões nos cascos e claudicações em suínos. **Boletim informativo de Pesquisa, Embrapa Suínos e Aves e Extensão**, ano 6, n.10, p.1-23, 1997.

MACLEAN, C.W. Acute laminitis in sows. **The Veterinary Record**, v. 83, n. 1, p. 71-75, 1968.

NILSSON, S.A. Laminitis in pigs. **Nordisk Veterinarmedicin**, v. 16, p. 128-139, 1964.

OSBORNE, H.G. Foot rot in pigs. **Australian Veterinary Journal**, v. 26, n. 11, p. 316-317, 1950.

RIEDELSEL, E.A.. **The Phalanges**. In: THRALL, D.E. Textbook of Veterinary Diagnostic Radiology. 4.ed. Philadelphia: W.B. Saunders, 2002, p. 269-294.

SOBESTIANSKY, J.; BARCELLOS, D.; MORES, N.; CARVALHO, L.F.; OLIVEIRA, S.; MORENO, A.M.; ROEHE, P.M. **Laminite**. In: SOBESTIANSKY, J.; BARCELLOS, D.; MORES, N.; CARVALHO, L.F.; OLIVEIRA, S. Clinica e Patologia Suina. Goiânia: Grafica Art3, 1999, p. 253-254.

SORI, T. Recent footrot outbreak in Debrezeit swine farm, central Ethiopia. **Journal of Veterinary Science**, v.6, n. 4, p. 367-368, p. 367-368, 2005.

TIRANTI, K.I.; MORRISON, R.B. Association between limb conformation and retention of sows through the second parity. **American Journal of Veterinary Research**, v.67, n.3, p.505-509, 2006.

VAN AMSTEL, S.R.; SHEARER, J.K. Abnormalities of hoof growth and development. **Veterinary Clinics of North America Food Animal Practice**, v. 17, n.1, p. 73-91, 2001.

WEAVER, A.D.; STEINER, A.; ST JEAN, G. **Lameness**. In: WEAVER, A.D.; STEINER, A.; ST JEAN, G. Bovine Surgery and Lameness. 2.ed. Oxford: Blackwell, 2005, p. 179-232.